

ORIGINAL ARTICLE

Adverse reactions to dermal fillers: A review of European experiences

P. ANDRE¹, N. J. LOWE², A. PARC², T. H. CLERICI³ & U. ZIMMERMANN³

¹Paris, France, ²Cranley Clinic, London, UK, and ³Department of Pathology, Ambroise Pare Hospital Paris, France

Abstract

Background. In Europe, numerous dermal fillers have been utilized for the past decade. A lot of drawbacks have been reported and sometimes, severe complications occurred.

Objective. Our purpose is to report the clinical aspects of the adverse reactions following injections of some of the dermal fillers. Histological aspects of complications are also described.

Results. Adverse reactions secondary to biodegradable products are usually time limited, but with the non-biodegradable products, we have observed severe, persistent, and recurrent complications. Histological examinations, in cases of non-biodegradable products, may show the presence and persistence of the filler.

Conclusion. For the moment, there is no ideal dermal filler. All fillers can lead to adverse events and we need to inform patients fully before injecting. Clinical studies with long-term follow-up before launching a new product on the market are recommended. We believe that in Europe, at present, the CE mark is not a guarantee of safety of dermal fillers.

Key words: Adverse reactions, dermal fillers, filler agents

Introduction

Several injectable materials have been used in cosmetic dermatology for the treatment of facial lines, atrophic lips and skin aging for the past decade. The naso-labial folds, the glabellar area, the wrinkles of the crow's feet and the lips are most often injected. In addition they have been used to increase the volume of the face, or to treat atrophic scars. Several different types of products have been utilized (1–3).

Some fillers need a double skin testing before injecting, others are not theoretically allergenic and according to companies do not require any test.

Many of these products were injected without adequate preliminary clinical testing and several adverse events have been documented (4).

patient did not remember the product that was injected. In other cases, surgery was performed to excise the reactive area for analysis by histology.

Adverse reactions

As we inject the skin, expected reactions include pain, bruising, swelling, erythema, dependent on the technique and on the needle that we use. Some fillers are very injection technique dependant.

These “common” adverse events are not described. Only unusual and or severe adverse reactions are reported. All these complications can be reported with any types of fillers but duration is dependent on the biodegradable character of the filler. It is important therefore to separate non-biodegradable from biodegradable products.

Materials and methods

Patients

We documented from our own patients' and referred patients' adverse reactions during the last decade.

Skin biopsy specimens

Skin biopsy specimens were obtained in selected cases of long-lasting and disfiguring lesions, or if the

Results

Non-biodegradable products

Silicone. Silicone was injected as a fluid of 350 centistoke of viscosity for more than 40 years. It is an oil containing polydimethylsiloxane polymers composed of silicon, oxygen, and methane molecules.

No true allergy to silicone has been documented and it has been shown that silicone has the least

reactivity of most foreign materials (4). Fluid silicone needs to be injected by the micro-droplet technique at monthly intervals (2). This is the only totally permanent product.

The mechanism of action is thought to be a combination of the displacement of the dermal connective tissue by silicone and the production of thin walled collagen capsules that surround the micro-droplets.

Most of expert advocates of silicone feel that the majority of adverse reactions are due to improper techniques (too superficial injections, too large volume), or due to utilization of impure silicone. In some very rare cases, delayed inflammatory nodular reactions have occurred many years after the injections (5). Reports of drifting are secondary to the injections of too large volume of silicone.

Histological aspect is quite particular (6) with the presence in the dermis of a diffuse granulomatous infiltrate made of histiocytes and multinucleated giant cells which contain small vacuoles. This infiltrate is dissociated by many, apparently empty, vacuoles of variable size and slightly irregular shape that are not birefringent under polarized light microscopy. There is collagen fibrosis. The association with birefringent foreign bodies in the cytoplasm of multinucleated cells is due to the impurities in the injected silicone (7).

For several years, silicone injections (350 cs) have been forbidden in most countries, including France and the USA.

Currently, there are two types of FDA-approved medical grade liquid injectable silicone for ophthalmology (retinal detachments) that are utilized ("off label") for soft tissue augmentation (Adatosil 5000—Bausch & Lomb Surgical; Silikon 1000—Alcon Lab), but there is no long-term follow-up. A new FDA approved study is currently under investigation (Silskin—RJ Development Corp) (8).

Artecoll (Rofil-MI, The Netherlands). Artecoll is a mixture of bovine collagen and of polymethylmethacrylate microspheres (PMMA) from 30 to 40 microns of diameter (9). This product has been on the market in Europe since 1993. It needs double skin testing before injections. Adverse reactions occur and are sometimes severe (10). We have observed immediate hypersensitivity reactions with local/or regional reactions (facial edema). But most of these adverse reactions appear several months or years later as delayed persistent granulomatous reactions, inflammatory or not, and often recurrent (Figure 1).

The histological aspects (11,12) of these reactions are quite typical, characterized by a diffuse granulomatous infiltrate involving the dermis, made of histiocytes, epithelioid cells, multinucleated giant cells and some lymphocytes. Multiple round vacuoles of varying size are identified between the inflammatory cells, described as mimicking fat cells.

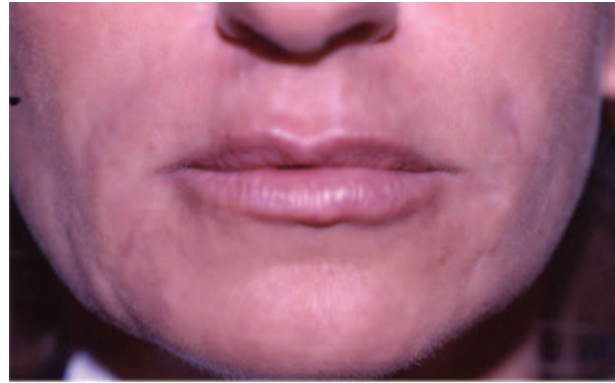

Figure 1. Three years after Artecoll* implantation: delayed inflammatory granulomatous reaction. (Polarized light $\times 100$) Birefringence of the cystic spaces.

Some sharply circumscribed translucent non-birefringent foreign bodies may be detected in the cystic spaces, corresponding to the implanted polymethylmethacrylate pearls (Figure 2).

Dermalive (Dermatech, France). Dermalive is another medical "plexiglas" utilized as filler device. It is a mixture of a non-animal hyaluronic acid and micro-particles of polyethylmethacrylate from 30 to 60 microns. No skin testing is necessary according to the company. We have seen several severe complications and adverse events (Figure 3). They are very similar to those of Artecoll but the incidence is really higher (P. Andre. Personal observations).

The histological aspects (6) are similar to those of Artecoll: in the dermis, diffuse and nodular granulomatous infiltrate, made of histiocytes, epithelioid cells and numerous multinucleated giant cells which contain asteroid bodies in their cytoplasm. The infiltrate is mixed with multiple cystic spaces of different shape and size containing translucent pink polygonal foreign bodies. There is no birefringence under polarized light microscopy (Figure 4).

Polyacrylamide. New products, derived from polyacrylamide, have been launched over the last

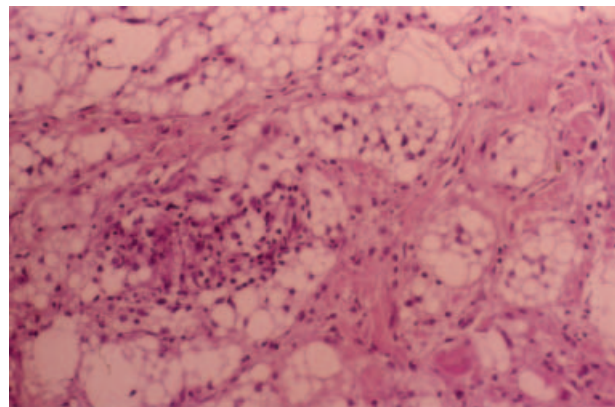


Figure 2. Granulomatous reaction with histiocytes, lymphocytes and mimicking fat cells made of microspheres of PMMA (H&E $\times 200$).

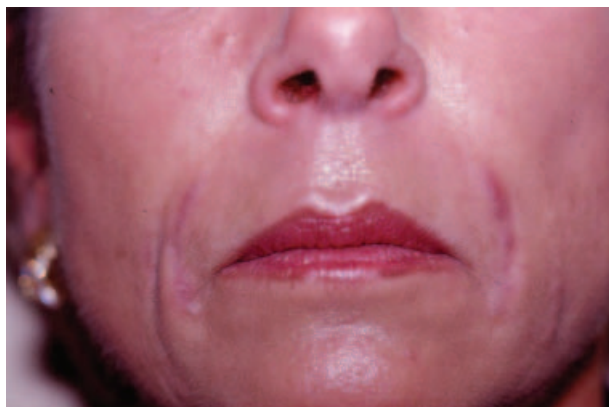

Figure 3. Delayed inflammatory granulomatous reaction after Dermalive® implantation.

few years. These products must be not degraded, as monomers of acrylamide are toxic. Acrylamide is a toxic substance that is capable of producing axonopathy by transection of neurons (13). Most of the products contain 2.5%–3% of polyacrylamide gel in water.

Evolution (Procytec, France), is a mixture of polyacrylamide and polyvinyl acid.

Aquamid (Contura SA, Switzerland) has been utilized since 2001.

Outline (Procytec, France), contains 3% polyacrylamide in water and according to the company is degraded to 50% after two years.

Some strong immediate reactions as redness and edema are described and occasional sterile abscess type delayed reactions (Figure 5).

Bio-Alcamid (Polymekon, Italy). Bio-Alcamid is a 4% polyalkyl-imide gel in water. It realizes an “endoprosthesis” and in case of unusual local reaction it seems possible to excise the gel by a small puncture and manual pressure.

All these medical devices appear to be more useful to increase volume than to treat wrinkles. The frequency of all these adverse events is not really known as no long-term clinical studies have been

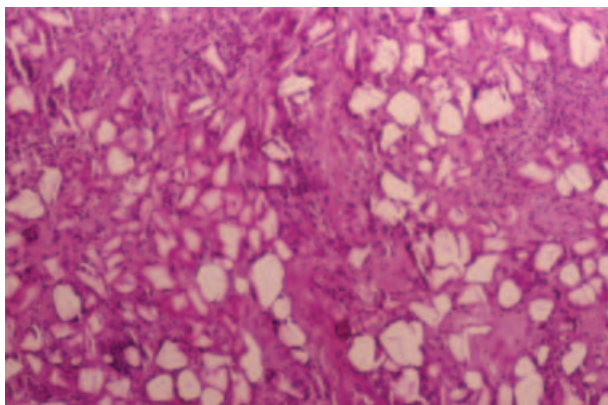


Figure 4. Granulomatous infiltrate in the dermis with histiocytes, epithelioid cells, multinucleated giant cells and cystic spaces of different sizes and shapes (H&E $\times 200$).

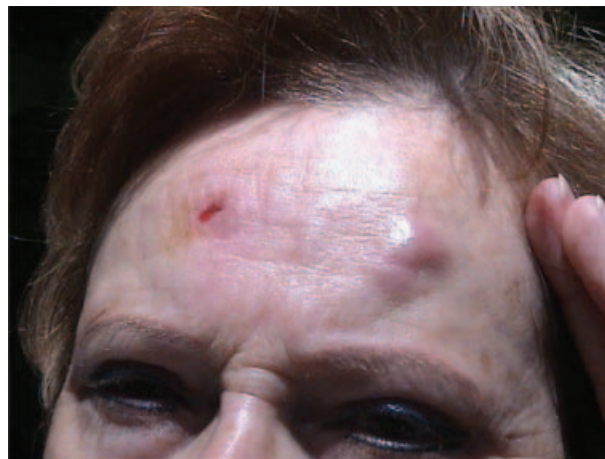

Figure 5. Sterile abscess after outline implantation.

carried out with any of these products. Treatment of these complications is not easy and may not be successful. We can inject the inflammatory nodules with a long-acting corticosteroid (triamcinolone, dexamethasone), alone or in association with 5 FU, or prescribe systemic corticosteroid or minocycline in case of siliconoma. Often, surgical excision is the only solution. Complications of these treatments have to be explained to patients.

Biodegradable products

Bovine collagen. Bovine collagen (Collagen Corporation, USA) was the gold standard as a biodegradable filler. Zyderm 1 was FDA approved in 1981, Zyderm 2 in 1983, Zyplast in 1985 (14). Several well conducted studies have proved his efficacy and safety. One of the requirements is the necessity to perform skin testing before injections. A double skin test is necessary (with a two-week interval) with examination one month after the second test. Between 4% and 5% of allergic patients are detected and excluded but even in the other treated patients, 1%–3% of them will present an hypersensitivity reaction (15,16). Antibodies against bovine collagen have been demonstrated (17).

Most of these adverse events will resolve spontaneously in a few weeks or months but a few cases of delayed recurrent inflammatory nodules for more than a year have been reported. Glabellar scarring, following necrosis and painful cystic reactions have also been reported (18).

Some aggravating factors are well recognized, including alcohol, sun, coffee, and menstruation.

Another drawback is potential risk of transmission of bovine particles and prions, since we know that bovine spongiform encephalopathy (BSE) has been occurring in many countries.

A new collagen source from human cadaver is now on the market, but we need a long-term follow-up to know its efficacy and safety. This is marketed as Cosmoderm® and Cosmoplast® in the USA.

Autologous collagen prepared from fat harvesting has no risk of hypersensitivity reaction, and infections are the only risks. The major drawback is to prepare it before injecting.

Hyaluronic acid (HA). Since 1996, hyaluronic acid (HA), a biodegradable product, has been introduced on the European market.

Biomatrix (NJ, USA) produces HA from rooster comb (Hylaform); it is an animal derived product.

Q-med (Uppsala, Sweden) manufactures HA by bacterial fermentation from specific strains of streptococci; it is a non-animal HA (Restylane, Perlane).

Corneal (France) manufactures another non-animal HA (Surgiderm).

Now, several other companies market their own HA. All these HAs are not comparable and some are lacking in follow-up to evaluate the duration and the safety of the product.

HA is a glycoaminoglycan polysaccharide (19) composed of alternating residues of the monosaccharide d-gluronic acid and N-acetyl-d-glucosamine present in the human body that has no species specificity.

Risk of allergic reactions is very low, and manufacturers suggest that there is no need for skin testing. In fact, there is a very small amount of proteins which can lead to some hypersensitivity reactions (20–23). Anti-HA antibodies have been demonstrated (24) but we do not know exactly the significance.

A retrospective European survey has evaluated the risk of important adverse reactions with the HA from Q-Med from 1997 to 2001 (23). A total of 4,320 patients were evaluated and 12,344 syringes were injected. From 1997 to 2001, 34 cases of hypersensitivity are reported: 16 cases of immediate hypersensitivity and 18 cases of delayed reactions. Global risk is 0.8%.

Since 2000, the load of proteins of the Q-Med product has decreased, and the incidence of hypersensitivity reactions has become around 0.6%.

As 50% of these reactions are immediate and resolved within less than three weeks, the risk of transient delayed reactions was around 0.3% with the old formulations (21). These are now significantly less frequent (less than 1 in 2000 treatments) with the current Q-Med products (Lowe NJ, in preparation). These remain the most used products in the UK and are very predictable.

Sterile abscess, livedoid pattern after intra vascular injection have been reported (23,25) (Figure 6). No systemic reactions have been reported.

Non-animal HA from the Q-Med company does not need skin testing.

In cases of “inflammatory” reactions, the histological aspects can be either a moderate lymphocytic infiltrate with some plasma cells in the dermis and

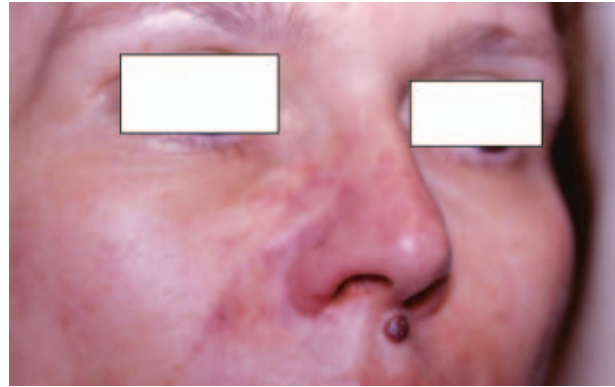


Figure 6. Livedoid aspect after Restylane* injection in the nasolabial fold.

the hypodermis (21,26) or a lymphocytic infiltrate with macrophages and presence of foreign body giant cells.

Profill (OVI SA, France). Profill was introduced on the French market in 1997. This product, a thermoelastic gel, called Lutrol F 127, is a polymer of hydroxy-polyethylene and hydroxy-polypropylene. This is a biodegradable product and according to the company, no risk of allergic reaction exists: no skin testing is necessary.

We have observed immediate reactions as edema and redness, but overall we have reported (27) several cases of lipoatrophy of the face (Figure 7). These lipoatrophy appeared months after injection of nasolabial folds. Pathogenesis is unclear, but we think that degradation products of Profill may interfere with lipid release of peripheral adipocytes.

Histological aspect is not specific: no foreign body reaction, no particular inflammatory reaction, but a severe fibrosis in the hypodermis.

The best treatment of these lipoatrophy is lipo-filling (28).

New-Fill/Sculptra (Aventis, France). New-Fill/Sculptra, a polymer of polylactic acid (PLA) is a fibrosing product. According to the company, it is

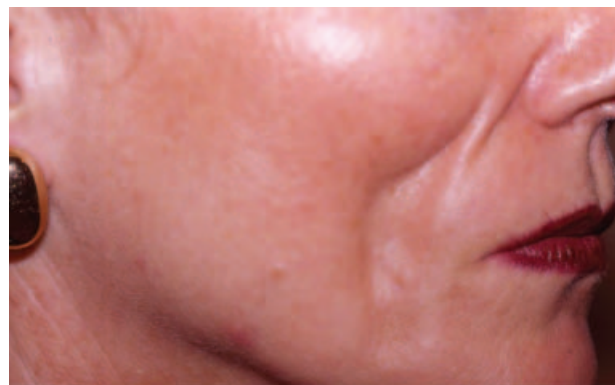

Figure 7. Delayed lipoatrophy of the face after Profill* implantation.

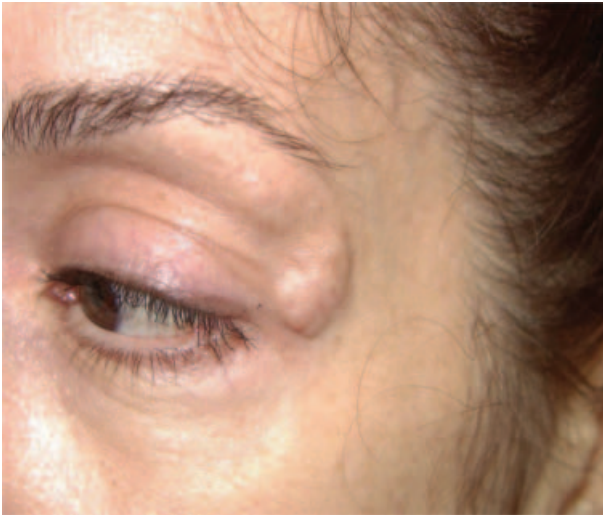


Figure 8. Cystic reaction after New-Fill* implantation.

biodegradable within three years. It is diluted usually with sterile water some hours before injection.

It has been utilized to treat wrinkles and severe HIV lipoatrophies. Many adverse events have been observed (Figure 8): micro- or macro-nodular cystic reactions, and inflammatory nodules. The incidence of nodules is more frequent with too superficial placement, too high a concentration of PLA and use in areas such as periorbital skin.

Histological aspect is characteristic: in the dermis, a granulomatous reaction made of histiocytes, epithelioid cells and multinucleated giant cells is present. The infiltrate is made of a lot of lymphocytes and we observe multiple cystic spaces. Under polarized light microscopy, there is a quite characteristic birefringence of these cystic spaces (Figures 9 and 10).

These complications last for many months or more. They may disappear under corticoid injections. Surgery is sometimes the only solution to improve the clinical aspect. The treatments of these

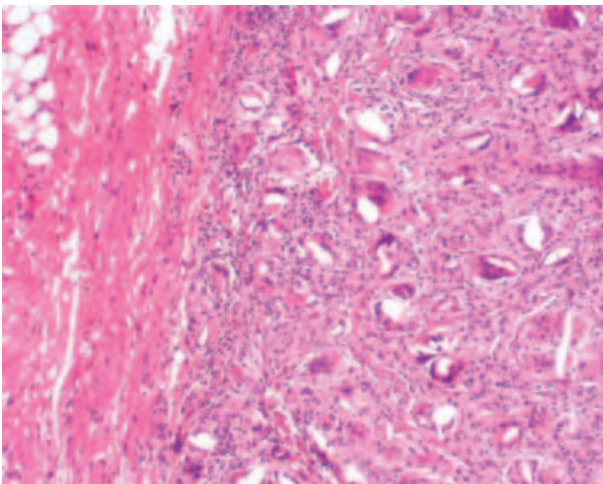


Figure 9. Granulomatous reaction in the dermis with histiocytes, epithelioid cells and cystic spaces (H&E $\times 200$).

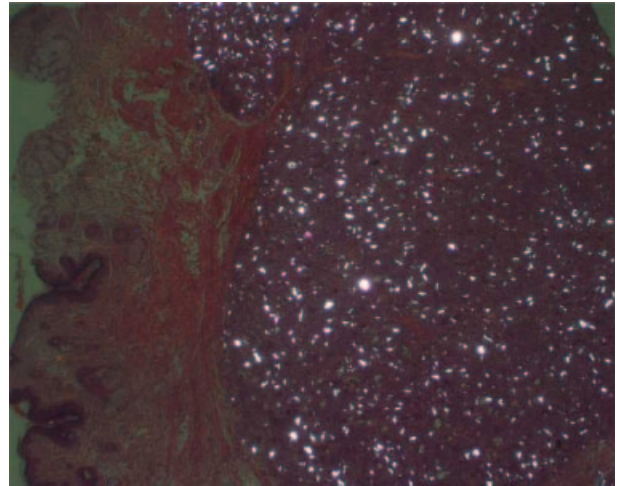


Figure 10. Birefringence of the cystic spaces (Polarized light $\times 100$).

complications are not easy but as with the biodegradable products, they may gradually disappear spontaneously. First, avoid the aggravating factors.

One of the authors (NJL) has treated over 500 patients with New-Fill (Sculptra) using much greater dilution than first reported here and with rare problems of nodules. Sites to be avoided are periorbital skin and dorsal hands. Care is needed near lips and neck to avoid nodule formation (NJ Lowe, in preparation).

Topical corticosteroids, intra-lesional corticosteroids alone, or in association with 5 FU, systemic corticosteroids, drainage of abscess, excisional surgery and lipo-filling can be discussed.

Conclusion

All fillers can give adverse events (29,30). Some need skin testing, others do not; skin testing cannot always eliminate risk of hypersensitivity or delayed foreign body reaction. In case of complication, the duration usually depends on the longevity of the product.

Sometimes, patients do not remember or were not informed of the filler that has been injected. In these cases, biopsy for histological examinations can demonstrate the nature of the filler.

Before injecting a non-biodegradable product, we need to inform the patient of risks, and for this reason we need to know the real incidence of them.

Before launching a new filler product, clinical studies must be carried out with a long-term follow-up.

References

1. Castrow FF II, Krull EA. Injectable collagen implant—update. *J Am Acad Dermatol.* 1983;9:889–93.
2. Orentreich D. Liquid injectable silicone: techniques for soft tissue augmentation. *Clin Plast Surg.* 2000;27:595–612.

3. Piacquadio D, Jarcho M, Goltz R. Evaluation of hylan b gel as a soft tissue augmentation implant material. *J Am Acad Dermatol.* 1997;36:544–9.
4. Gonzalez UM, Stevens E, Loewe P, Vargas de la Cruz J, Noble G. Preliminary report on the subcutaneous perfusion of dimethylpolysiloxane to increase volume and alter regional contour. *Br J Plast Surg.* 1967;20:424–8.
5. Rapaport MJ. Silicon injections revisited. *Dermatol Surg.* 2002;28:594–5.
6. Requena C, Izquierdo MJ, Navarro M, Martinez A, Vilata JJ, Botella R, et al. Adverse reactions to injectable aesthetic microimplants. *Am J Dermatopathol.* 2001;23:197–202.
7. Ackerman AB, Jacobson M, Vitale P. In: Ackerman AB, editor. *Clues to diagnosis in dermatopathology I.* Chicago: ASCP Press, 1991. p. 394–6.
8. Brown L, Franck P. What's new in fillers? *J Drugs Dermatol.* 2003;3:250–3.
9. Lemperle G, Hazan-Gauthier N, Lemperle M. PMMA microspheres (Artecoll) for skin and soft tissue augmentation. Clinical investigations. *Plast Reconstr Surg.* 1995;96:627–34.
10. Alcalay J, Alcalay R, Gat A, Yorav S. Late-onset granulomatous reactions to Artecoll. *Dermatol Surg.* 2003;29:859–62.
11. Lemperle G, Pomano J, Busso M. Soft tissue augmentation with Artecoll: 10 year history, indications, techniques and complications. *Dermatol Surg.* 2003;29:573–87.
12. Rudolph CM, Soyer HP, Schulle-Petrovic S, Kerl H. Foreign body granulomas due to injectable aesthetic microimplants. *Am J Pathol.* 1999;23:113–17.
13. Smith E, Oehme F. Acrylamide and polyacrylamide: review of production, use, environmental fate and neurotoxicity. *Reviews on Environ Health.* 1991;4:215–27.
14. Tromovitch TA, Stegman SJ, Glogau RG. Zyderm collagen: implantation technics. *J Am Acad Dermatol.* 1984;10:273–8.
15. Klein AW. Indications and implantation techniques for the various formulations of injectable collagen. *J Dermatol Surg Oncol.* 1988;14:27–30.
16. Klein AW. In favor of double testing. *J Dermatol Surg Oncol.* 1989;15:263.
17. Vanderveen EE, McCoy JP Jr, Schade W, Kapur JJ, Hamilton T, Ragsdale C, et al. The association of HLA and immune responses to bovine collagen implants. *Arch Dermatol.* 1986;122:650–4.
18. Hanke CW, Higley HR, Jolivet DM, Swanson NA, Stegman SJ. Abscess formation and local necrosis after treatment with Zyderm or Zyplast collagen implant. *J Am Acad Dermatol.* 1991;25:319–26.
19. Goa KL, Benfield P. Hyaluronic acid. A review of its pharmacology and use as a surgical aid in ophthalmology, and its therapeutic potential in joint disease and wound healing. *Drugs.* 1994;47:536–66.
20. Lupton JR, Alster TS. Cutaneous hypersensitivity reaction to injectable hyaluronic acid gel. *Dermatol Surg.* 2000;26:135–7.
21. Lowe NJ, Maxwell CA, Lowe P, Duick MG, Shaw K. Hyaluronic acid skin fillers: adverse reactions and skin testing. *J Am Acad Dermatol.* 2001;45:930–3.
22. Friedman PM, Mafong EA, Kauvar AN, Geronemus R. Safety data of injectable non animal stabilized hyaluronic acid gel for soft tissue augmentation. *Dermatol Surg.* 2002;28:491–5.
23. Andre P. Evaluation of the safety of a non animal hyaluronic acid (NASHA—Q-Med) in European countries: a retrospective study from 1997 to 2001. *J Eur Acad Dermatol Venereol.* 2004;18:422–5.
24. Micheels P. Human anti-hyaluronic acid antibodies: is it possible? *Dermatol Surg.* 2001;27:185–91.
25. Schanz S, Schippert W, Ulmer A, Rassner G, Fierlbeck G. Arterial embolization caused by injection of hyaluronic acid (Restylane). *Br J Dermatol.* 2002;146:928–9.
26. Duranti F, Salti G, Bovani B, Calandra M, Rosati ML. Injectable hyaluronic acid gel for soft tissue augmentation: a clinical and histological study. *Dermatol Surg.* 1998;24:1317–25.
27. Andre P, Wechsler J, Revuz J. Facial lipoatrophy: report of five cases after injection of synthetic filler into naso-labial folds. *J Cos Derm.* 2002;3:120–3.
28. Andre P. Facial lipoatrophy secondary to a new filler device (Profill) treated by lipofilling. *J Cos Derm.* 2002;2:59–61.
29. Lowe NJ. Adverse reactions to dermal fillers. *J Derm Surgery;* in press.
30. Andre P, Kaminer M. Soft tissue augmentation: an international perspective. *Semin Cutan Med Surg.* 2004;23:4.

Copyright of *Journal of Cosmetic & Laser Therapy* is the property of Taylor & Francis Ltd and its content may not be copied or emailed to multiple sites or posted to a listserv without the copyright holder's express written permission. However, users may print, download, or email articles for individual use.