
Five Percent Lidocaine Cream Applied Simultaneously to the Skin and Mucosa of the Lips Creates Excellent Anesthesia for Filler Injections

KEVIN C. SMITH, BA, BSc, MD, FACP, FRCPC (DERMATOLOGY), AND MICHAEL MELNYCHUK, BSc, DDS

Private Practice, Niagara Falls, Ontario, Canada

BACKGROUND. Injection of filler substances into the lips is painful, and many patients also find the injection of local or regional anesthesia into the lips painful.

OBJECTIVE. To develop a highly effective and painless form of anesthesia to facilitate injection of filler substances into the lips.

METHODS. Five percent lidocaine cream was applied simultaneously to the skin, vermilion, and mucosa of the lips (with the use of a barrier to keep the cream in contact with the mucosa and out of the rest of the mouth) for 20 to 30 minutes.

RESULTS. Profound anesthesia of the lips was reliably produced, with no complications.

CONCLUSIONS. This “anesthetic cream block” is easier to perform and better tolerated than injectable anesthetics. Use of this technique is likely to expand the range of physicians who perform filler injections on the lips and will probably also expand the range of patients who wish to have filler injections done on their lips and who (because they had little or no discomfort) are willing to return for additional filler injections in the future.

SAMPLES OF MAXILENE AND LMX5 WERE PROVIDED FOR THE STUDY. KEVIN C. SMITH, MD, HAS RECEIVED SPONSORSHIP FOR LECTURES BY CANDERM AND FERNDAL LABORATORIES.

THE HIGH concentration of sensory nerves in the lips (which make kissing so much fun) also makes it very painful to inject filler substances into the lips. Anesthesia is usually essential before the lips are injected with fillers, such as hyaluronic acid or collagen. Patients often find the injection of local or regional anesthesia to be unpleasant. Some physicians have difficulty mastering and maintaining the skills necessary to provide local or regional anesthesia successfully and with minimal discomfort. Topical anesthetics, when applied only to the vermilion of the lips and to the perioral skin, often produce inadequate anesthesia.

Based on the observation (unpublished data, 2002) that application of anesthetic cream to the mucosal surface of the upper lip can reduce the discomfort of laser hair removal, the first author has found that excellent anesthesia can be reliably induced when lidocaine cream is applied simultaneously to the mucosal surfaces of the lips, including the anterior mucosae of the anterior labioalveolar sulci (sometimes referred to as the anterior mucosae of the oral vestibule), in addition to the vermilion of the lips and a 1 cm margin of skin around the vermilion border of the lips. Anesthetic cream applied to the mucosae adjacent to the lips produces the extra degree of anesthesia necessary for topical anesthesia of the lips to be highly effective and reliable by anesthetizing the mucosal portions of the max-

illary branch of the second division of the cranial nerve serving the upper lip and the mandibular branch of the third division of the cranial nerve serving the lower lip.

Extensive work by others has shown that application of lidocaine^{1,2} or a eutectic mixture of 2.5% lidocaine and 2.5% prilocaine³ to the oral or tracheobronchial mucosa of adults produced blood levels well below the threshold for toxicity (5 µg/mL). The total amounts of lidocaine applied in the work referenced above were considerably greater than the amount of lidocaine (75 mg) in the maximum of 1.5 g of 5% lidocaine cream applied to the oral mucosa in the procedure described in this article. It has also been shown that the application of 5% lidocaine under occlusion to areas on the skin of up to 420 cm² (far greater than the 40 cm² perioral area to which 5% lidocaine cream is applied in the technique described in this article) for up to 12 hours produces blood levels of lidocaine below 0.1 µg/mL.⁴ It is reasonable to expect that the sum of the systemic absorption of lidocaine from both mucosal and skin exposure to 5% lidocaine cream in the technique described here is likely to be far below the threshold for systemic toxicity. In view of this body of research, it was not considered necessary to obtain serum lidocaine levels from the patients described in this article, and there has been no clinical evidence of lidocaine toxicity in any of these patients or subsequent patients. The use of a barrier that reduces the amount of lidocaine cream that gets on to the tongue and posterior oropharynx probably helps limit the amount of systemic uptake of lidocaine.

Address correspondence and reprint requests to: Kevin C. Smith, BA, BSc, MD, FACP, FRCPC (Dermatology), #201 - 6453 Morrison Street, Niagara Falls, ON L2E 7H1, Canada, or e-mail: ksmithderm@aol.com; www.smithlaser.com

When topical anesthesia is applied to the mucosal surface of the lips and to the anterior labioalveolar sulci, it is important to use a barrier (1) to keep the anesthetic cream in contact with the mucosae and thus maintain a high concentration gradient between the anesthetic cream layer and the mucosae and (2) to keep the anesthetic cream from getting into the oropharynx and causing unwanted anesthesia of the tongue and throat.

A 5 × 10 cm piece of nonadherent pad (eg, Telfa) produces an excellent, inexpensive barrier. The nonadherent pad should have slits cut in it, as illustrated in Figure 1, to accommodate the frenula of the upper and lower lips (Figure 2) and a slit cut lengthwise so that the patient can breathe through the mouth or speak if necessary during the 20 to 30 minutes that the pad and anesthetic cream are in place. It is easiest to position the nonadherent pad if the patient keeps the teeth together and relaxes the lips. Keep-

ing the teeth together prevents the nonadherent pad from getting into the pharynx behind the teeth, and if the lips are relaxed, it is easy to lift them away from the teeth to facilitate placement of the nonadherent pad (A. Berlinger, personal communication, September 14, 2004).

After the nonadherent pad described above has been placed between the teeth and the mucosal surface of the lips, anesthetic cream is generously applied to the mucosal surfaces of the lips and to the anterior labioalveolar sulci. The first author has found it convenient to put about 1.5 g of cream on a tongue depressor and then use the tongue depressor to apply the cream to the mucosal surfaces. The tongue depressor is then used to apply another 2.5 g of cream to the vermilion border of the lips and to a 1 cm strip of skin around the vermilion border of the lips, rather like putting icing on a cake. A good rule of thumb when applying anesthetic cream to the vermilion of the lips and the skin is that anesthetic cream should be applied thickly enough that the skin cannot be seen. This will ensure that the cream layer is thick enough to maximize the concentration gradient of anesthetic into the skin. The material used by the first author has been Maxilene 5% lidocaine cream and LMX5 5% lidocaine cream, both obtained as samples from Ferndale Laboratories (Ferndale, MI, USA).

The onset of anesthesia with an anesthetic cream block, as described above, is very smooth, with little of the “pins-and-needles” sensation that is commonly felt after the injection of local or regional anesthesia. Patients have been successfully injected with filler substances, such as Juvederm (INAMED Aesthetics, Santa Barbara, CA, USA), Restylane (Medicis, Inc., Scottsdale, AZ, USA), Cosmoplast (INAMED), and Artecoll (Canderm Pharma Inc., St-Laurent, PQ, Canada), as early as 15 minutes after application of the anesthetic cream, but it is my practice to wait 20 to 30 minutes if possible. It is a good idea to set a timer on the outside of the treatment room door (eg, Radio Shack Clip-On Digital Timer 63-878) so that the physician and staff will be alerted when the anesthetic has been in place for the desired amount of time. Although this technique produces excellent and reliable anesthesia for the injection of collagen-based filling substances that contain lidocaine (eg, Cosmoplast and Artecoll), there is a greater degree of discomfort when hyaluronic acid-based products, such as Restylane, are injected, and most patients prefer injectable to topical anesthesia when a hyaluronic acid filler is to be administered. For this reason, it was not possible to include patients being injected with hyaluronic acid fillers in this series of observations.

When anesthesia has been achieved, the nonadherent pad is removed from the mouth, and anesthetic cream is wiped from the oral mucosae, lips, and skin with gauze. The filler substance of choice is then injected into the vermilion border and/or the wet-dry junction of the lips and sometimes the melomental lines. To further reduce tissue trauma and to reduce the risk of bleeding or bruising, the

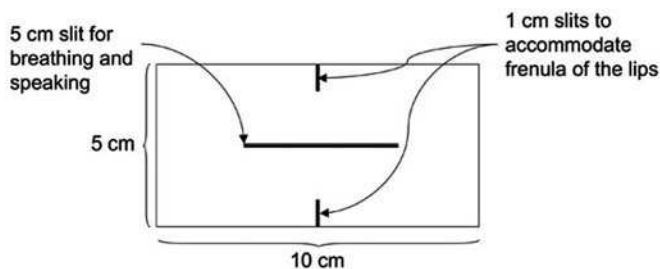


Figure 1. Diagram showing the dimensions of the nonadherent pad and positions of slits to accommodate the frenula of the lips and an opening for breathing and talking.

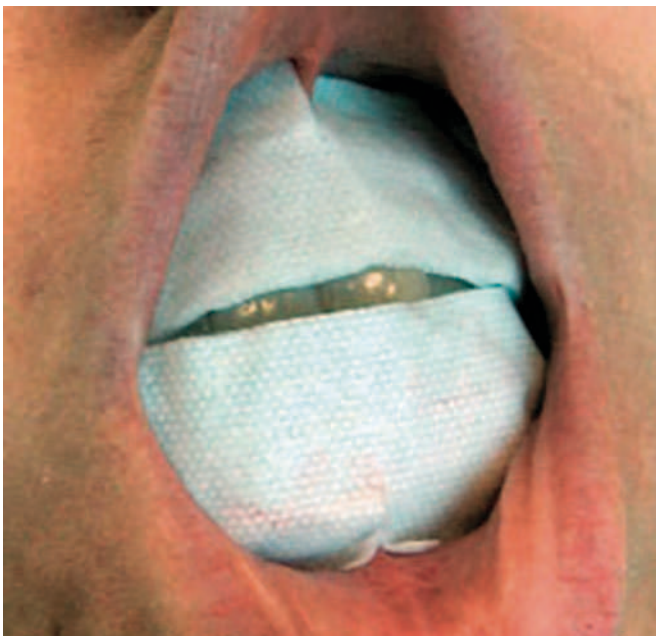

Figure 2. Nonadherent pad in position. Note slits at the midpoint of the superior and inferior margins to accommodate the frenula of the lips and the lateral slit in the middle so that the patient can breathe or speak while the anesthetic is in place.

first author injects all fillers using the 30-gauge MaxFLO needle (Richard-James, Inc., Peabody, MA, USA) (available from Canderm Inc, USA; Clarke Medical, Canada), which has the internal lumen of a 27-gauge needle. Anesthesia starts to dissipate about 10 minutes after the cream is removed and has resolved within about 45 minutes. There is little or no dysesthesia as the anesthesia resolves.

Retrospective review of the charts of seven consecutive patients (Table 1) who used a visual analogue pain scale to compare the total amount of discomfort (administration of anesthetic plus administration of lidocaine-containing filler substance in the lips) when (1) local or regional anesthesia (eg, "dental block") was performed by the first author or another physician, and (2) a subsequent session in which only anesthetic cream block was used.

Table 1. Visual Analogue Pain Scale*

<i>Patient and Filler</i>	<i>Dental Block</i>	<i>Anesthetic Cream Block</i>
1: Artecoll	85	15
2†: Artecoll	98	16
3: Artecoll	71	0
4‡: Cosmoplast	86	10
Cosmoplast		0
5: Artecoll	73	12
6: Artecoll	95	10
7: Artecoll	60	2

*100 mm; 0 = no pain; 100 = worst possible pain. Patients were asked to rate the total discomfort (including administration of topical or injected anesthetic) of the procedure. In all cases, patients were asked to recall and rate the total discomfort of the previous treatment session in which injectable anesthetic was used and then to rate the total discomfort of the treatment session in which a cream block of the lips was used instead of injectable anesthetic.

†Patients 2 and 4 were so pleased with the anesthetic cream block that patient 2 had three syringes of Artecoll instead of the two that were scheduled and patient 4 returned the next day for an additional two syringes of Cosmoplast at the wet-dry junction of the lips and on that occasion rated her total discomfort as 0.

In all cases, patients preferred anesthetic cream block of the lips to the previous treatment in which regional anesthesia had been used. Additional advantages of using an anesthetic cream block on the lips instead of local or regional anesthesia (eg, dental block) include the following:

1. There is no distortion of lip geometry secondary to asymmetric relaxation caused by local anesthesia of muscles, such as the zygomaticus major and minor, the levator and depressor labii, and the depressor angularis ori.
2. Local vasoconstriction caused by the topical anesthetic reduces the chance of bleeding or bruising.

In conclusion, the simultaneous application of 5% lidocaine cream to the skin, vermilion, and mucosa of the lips (with the use of a barrier to keep the cream in contact with the mucosa and out of the rest of the mouth) for 20 to 30 minutes reliably produces profound anesthesia of the lips and is better tolerated than injectable anesthetics. The use of anesthetic cream block for the lips is likely to expand the range of physicians who perform filler injections on the lips and will probably also expand the pool of patients who are willing to have such treatment and who wish to return for additional treatment after a good initial experience.

References

1. Loukides S, Katsoulis K, Tsarpalis K, et al. Serum concentrations of lignocaine before, during and after fiberoptic bronchoscopy. *Respiration* 2000;67:13-7.
2. Larijani GE, Cypel D, Gratz I, et al. The efficacy and safety of EMLA cream for awake fiberoptic endotracheal intubation. *Anesth Analg* 2000;91:1024-6.
3. Vickers ER, Marzbani N, Gerzina TM, et al. Pharmacokinetics of EMLA cream 5% application to oral mucosa. *Anesth Prog* 1997;44:32-7.
4. Rowbotham MC, Davies PS, Verkempinck C, Galer BS. Lidocaine patch: double-blind controlled study of a new treatment method for post-herpetic neuralgia. *Pain* 1996;65:39-44.

Copyright of Dermatologic Surgery is the property of B.C. Decker Inc. and its content may not be copied or emailed to multiple sites or posted to a listserv without the copyright holder's express written permission. However, users may print, download, or email articles for individual use.